B. Pharm (1st Year)
Anatomy and Physiology
BP-201T (Solution)

Section - A.

(a). Fore-brain consist of - Cerebrum, olfactory lobes and Diencephalon.

(b). Myelin sheath is made up of - Schwann cell.

(c). Movement of Nerve impulse across Node of Ranvier is called - Saltatory Movement.

(d). Duct of Parotid gland is called Stenson's duct.

(e). Pneumotaxic centre is located in - Pons

Section - B.

(a). Structure of Hypothalamus. →

→ Hypothalamus is the last part of Fore-brain.

→ It's cavity is called IIIrd ventricle.

→ Roof of Diencephalon is called Epithalamus. It consist of Pineal gland and choroid Plexus.

→ Pineal gland Secrete Melatonin harmone and Choroid plexus Secrete C.S.F.

→ Lateral walls (upper portion) of Diencephalon is called as Thalamus. It act as a relay centre for Sensory and Motor informations.

→ The Floor of Diencephalon is called 'Hypothalamus' through which Pituitary gland is attached with the help of Infundibulum. Hypothalamus

Scanned with CamScanner

act as Connecting link between Nervous System and Endocrine System. It controls involuntary activities of Internal organs. It is a centre of Anger, Agression, emotions, Hunger, thirst, Satiety, Happiness.

(b). Composition of Cerebrospinal Fluid (C.S.F) →.

C.S.F consist of 99.5% water and 0.5% other Substances. The other Substances includes- 60-70 mg%. glucose, Ammonia, urea, Protein, Some ions like Na^+, K^+, Ca^+, Cl^-, HCO_3^- ions. It provide Nutrition to various parts of the brain, act as a Shock absorber, and protects different parts of the brain from various Infections.

(c). Structure of Nerve cell →.

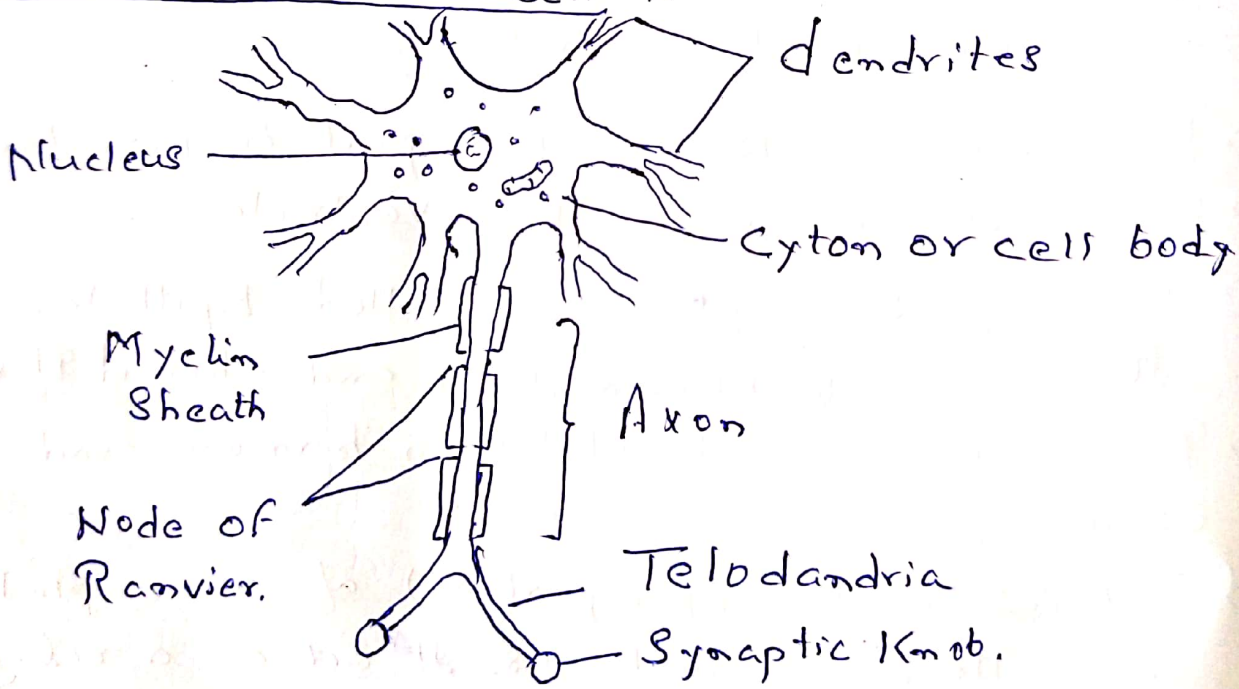

Nerve cell consist of a circular body called 'Cyton' or 'cell body.' Two types of projections arises from Cyton- Projections which are

Scanned with CamScanner

Short in size and more than one in number are called 'Dendrites,' and a single long projection is called 'Axon: The cyton consist of Nucleus, various cell organelles and Nissel's granules. The terminal end of Axon have branches called 'Telondandria.' The terminal end of Telodandria have Knob-like structures called Synaptic-Knob. The Axon is covered by Myelin-sheath. Gaps in the Myelin-sheath is called "Node of Ranvier"

Section-C

Q. No. 3 →

(a) → The cerebrum is the largest part of human brain. It's holloo cavity is called IInd ventricle. The wall of cerebrum is divided into an outer cortex made up of gray matter, and inner medullary layer made up of white matter. The surface of the cerebrum is folded into many folds. The elevations of the folds are called 'Gyri' and the depressions are called Sulci. The cerebrum is divided into 5-lobes - Frontal, Parietal, Temporal, occipital, and Insula lobes by less deep fissures. It's main functions are thinking, memory, judgement, planning, emotions. Like cerebrum, cerebellum is also divided into two lobes - outer layer made up of gray matter, and Inner solid part made up of white matter. Both these cerebral hemispheres are connected in the middle by a stalk-like structure called vermis. The surface of the cerebellum consist of many parallel folds called 'Folia'

Scanned with CamScanner

(b). Structure of Human Teeth. →.

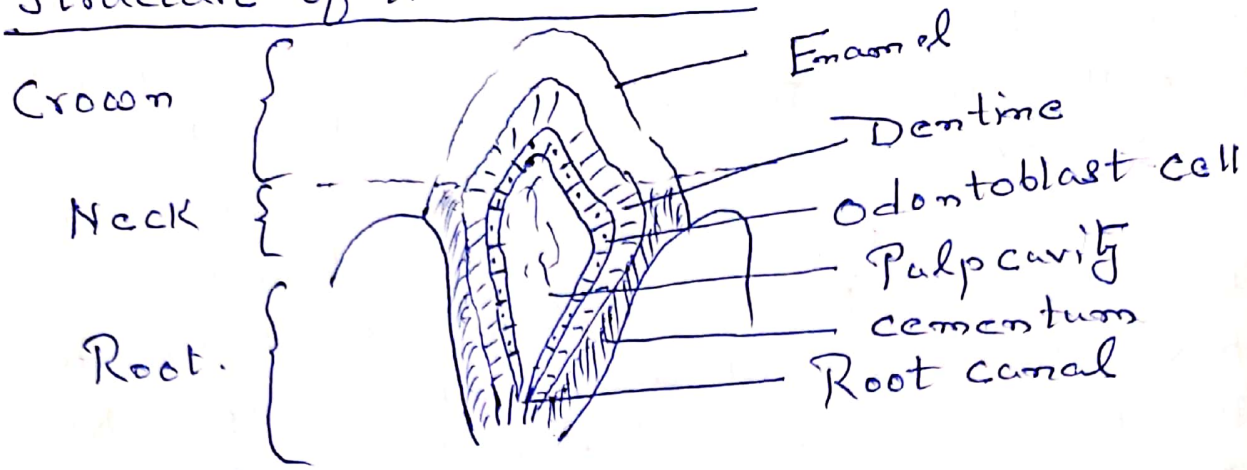

The Human teeth is divided into - Crown, Neck and Root. It has a hollow cavity called Pulp cavity surrounded by an epithelium of odontoblast cells. The Pulp cavity consist of blood vessels, Nerves, and lymph vessels, opens out through a narrow canal called Root canal. The pulp cavity is surrounded by a thick layer of dentine, containing many transverse canaliculi, in which projections of odontoblast cells are present. In the crown the dentine is surrounded by a hardest substance of the human body. It is called 'Enamel', made up of $CaPO_4$ and $CaSO_4$. In neck and Root, the dentine is covered by another hard substance called Cementum.

Q. No. 4 →

(a). Nerve Impulse Conduction. →

It occurs by two processes -:

(i). Resting membrane Potential. → At resting stage, the Na^+ channels of the Axolemma remains closed, therefore the is accumulation of large amount of Na^+ takes place outside the Axolemma in ECF, which attract -ve charged ions located on the innerside. Thus, the axolemma

Scanned with CamScanner

becomes polarised, and −70mv potential is generated. It is called Resting membrane potential.

(ii). Action Potential → When a stimulus is given to axolemma, the closed Na^+ channels opens, and large influx of Na^+ takes place from ECF to Axoplasm. As a result the +45mv potential is developed on the inner side of Axolemma. It is called Action potential.

When action potential reaches, the nerve endings, the Neurotransmitters are released into the Synaptic cleft, which set up wave of depolarisation (+45mv) in the next neuron.

(b). → Structure of Spinal cord. →

- length - 42 - 45 cm.
- Hollow cavity is called central canal or Neurocoel lined by Ependymal epithelium.
- Wall consist of outer layer of white matter and Inner layer of graymatter. The gray matter form - 3 - projection - Dorsal gray horn, lateral gray horn and ventral gray horn. The dorsal gray horn contains Roots of Sensory Nerve fibres and ventral gray horn contains roots of Motor Nerve fibres.

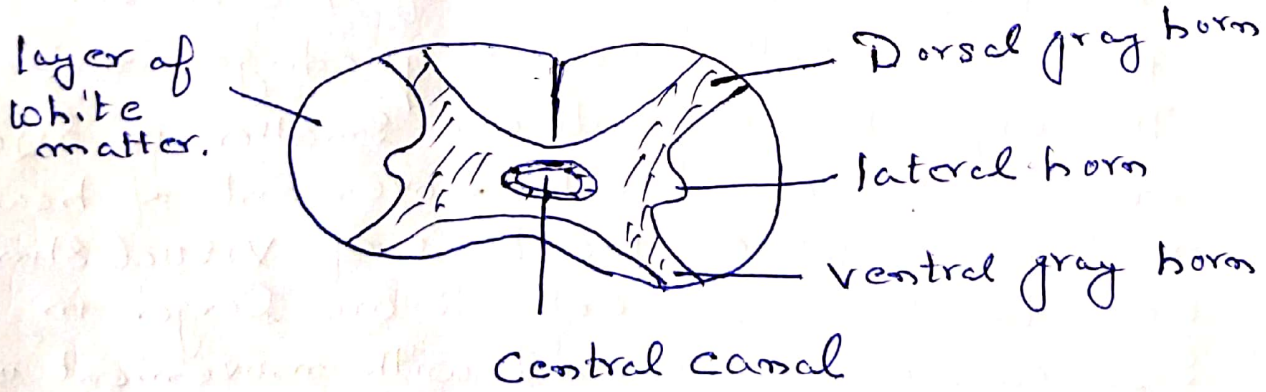

Scanned with CamScanner

The brain tissue is covered with 3-layers of Meninges - outer Duramater, middle - Arachnoid and innermost piamater. Between Duramater and Arachnoid sub-dural space is present, filled with serous fluid, while, the space between Arachnoid and Piamater is called sub-Arachnoid space filled with C.S.F. Duramater is thick, non-vascular layer made up of fibrous connective tissue, Arachnoid is also a non-vascular layer, made up of collagen and elastin fibres, and Piamater is highly vascular layer.

(b). Structure and Functions of Mid-brain

(1). It is 2.5cm long middle part of brain.

(2). It's hollow cavity is called cerebral aqueduct.

(3). At the Anterior end a pair of cerebral peduncles are present consisting of sensory and Motor Nerve fibres.

(4). The posterior part consist of 4-circular projections called 'Corpora quadrigemina'. The upper two colliculi are smaller in size and are concerned with movement of head, neck and eyes on the basis of visual stimuli, while the lower two colliculi are larger in size and are concerned with movement of head and Trunk on the basis of Auditory stimuli

Scanned with CamScanner